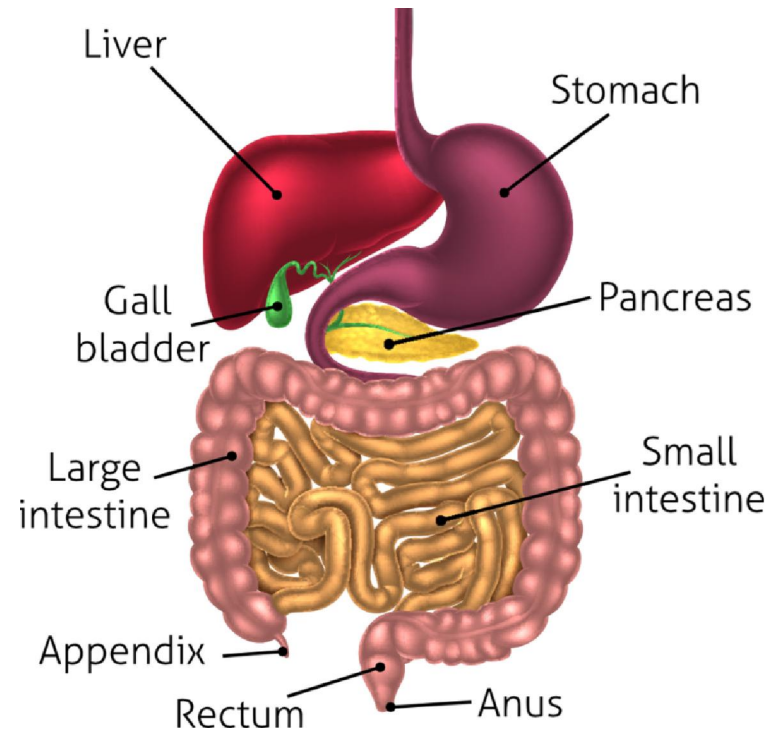


The Digestive System



1

Dr. Bhagat Singh Jaiswal
Assistant Professor (Pharmacology)
School of Studies in Pharmaceutical Sciences
Jiwaji University
Gwalior

- The digestive system describes the *alimentary canal, its accessory organs and a variety of digestive processes that* prepare food eaten in the diet for absorption. The alimentary canal begins at the mouth, passes through the thorax, abdomen and pelvis and ends at the anus.
- The digestive processes gradually break down the foods eaten until they are in a form suitable for absorption. For example, meat, even when cooked, is chemically too complex to be absorbed from the alimentary canal. Digestion releases its constituents:
- Amino acids, mineral salts, fat and vitamins. Digestive *enzymes responsible for these changes are secreted* into the canal by specialised glands, some of which are in the walls of the canal and some outside the canal, but with ducts leading into it.

The activities of the digestive system can be grouped under five main headings.

A. Ingestion. This is the taking of food into the alimentary tract, i.e. eating and drinking.

B. Propulsion. This mixes and moves the contents along the alimentary tract.

C. Digestion. This consists of:

mechanical breakdown of food by, e.g. mastication (chewing)

chemical digestion of food into small molecules by enzymes

a. Absorption. This is the process by which digested food

substances pass through the walls of some organs of the alimentary canal into the blood and lymph capillaries for circulation and use by body cells.

a. Elimination. Food substances that have been eaten but

cannot be digested and absorbed are excreted from the alimentary canal as *faeces* by the process of defaecation.

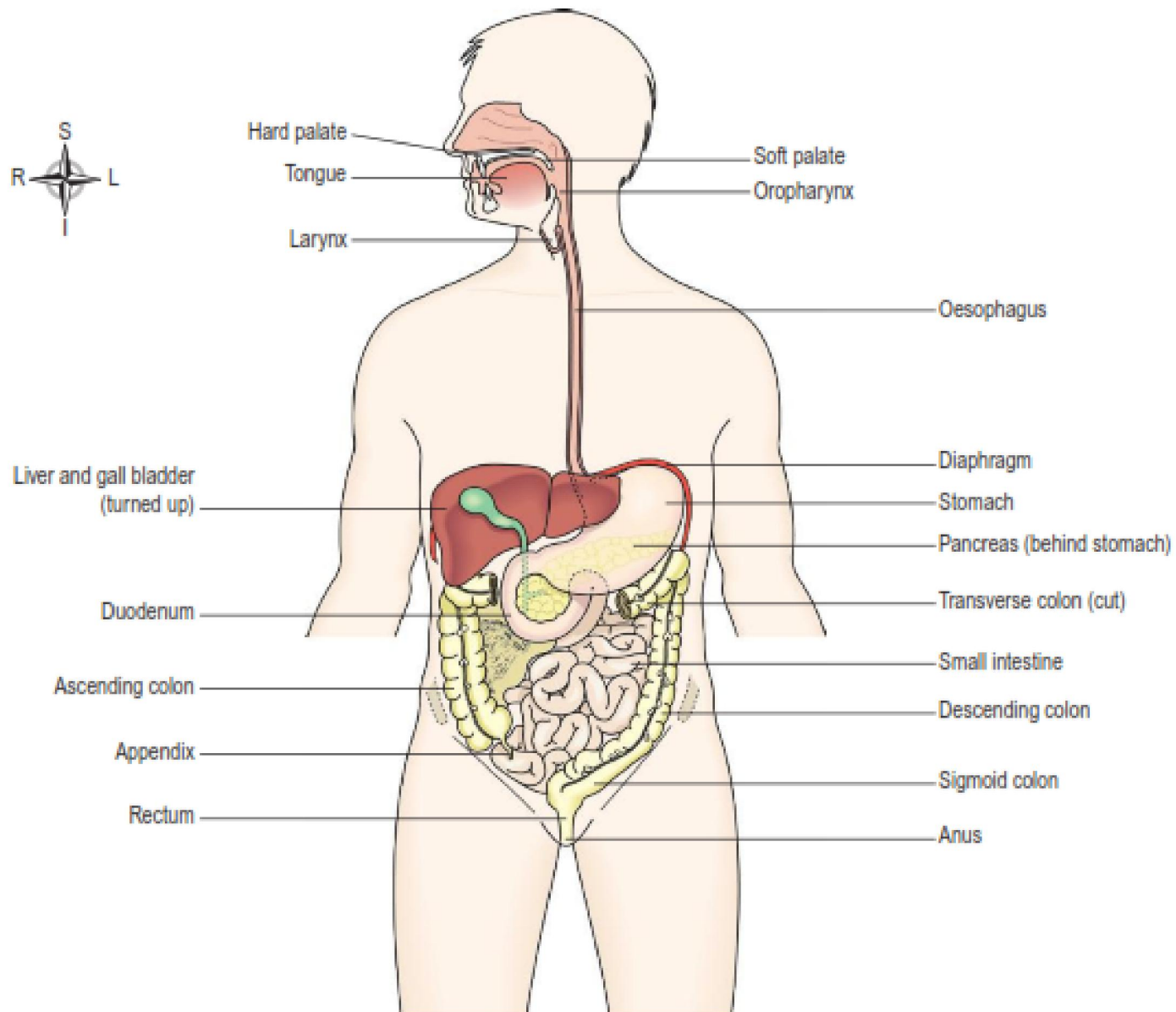


Fig: The digestive system

Organs of the Digestive System

A) Alimentary canal

Also known as the gastrointestinal (GI) tract, this is essentially a long tube through which food passes. It commences at the mouth and terminates at the anus, and the various organs along its length have different functions, although structurally they are remarkably similar. The parts are:

- ✓ Mouth
- ✓ Pharynx
- ✓ Oesophagus
- ✓ Stomach
- ✓ Small intestine
- ✓ Large intestine
- ✓ Rectum and anal canal

B) Accessory organs

Various secretions are poured into the alimentary tract, some by glands in the lining membrane of the organs, e.g. gastric juice secreted by glands in the lining of the stomach, and some by glands situated outside the tract, and these are as follows:

- ✓ Three pairs of salivary glands
- ✓ The pancreas
- ✓ The liver and biliary tract.

Stomach

The stomach is a **J-shaped** dilated portion of the alimentary tract. The stomach is divided into **three regions: the *fundus*, the *body* and the *pylorus***. At the distal end of the *pylorus* is the pyloric sphincter, guarding the opening between the stomach and the duodenum.

Organs associated with the stomach

Anteriorly – left lobe of liver and anterior abdominal wall

Posteriorly – abdominal aorta, pancreas, spleen, left kidney and adrenal gland

Superiorly – diaphragm, oesophagus and left lobe of liver

Inferiorly – transverse colon and small intestine

To the left – diaphragm and spleen

To the right – liver and duodenum

Structure of the stomach

The stomach is continuous with the oesophagus at the cardiac sphincter and with the duodenum at the pyloric sphincter. It has two curvatures. The *lesser curvature* is short, lies on the posterior surface of the stomach and is the downward continuation of the posterior wall of the oesophagus. Just before the pyloric sphincter it curves upwards to complete the J shape.

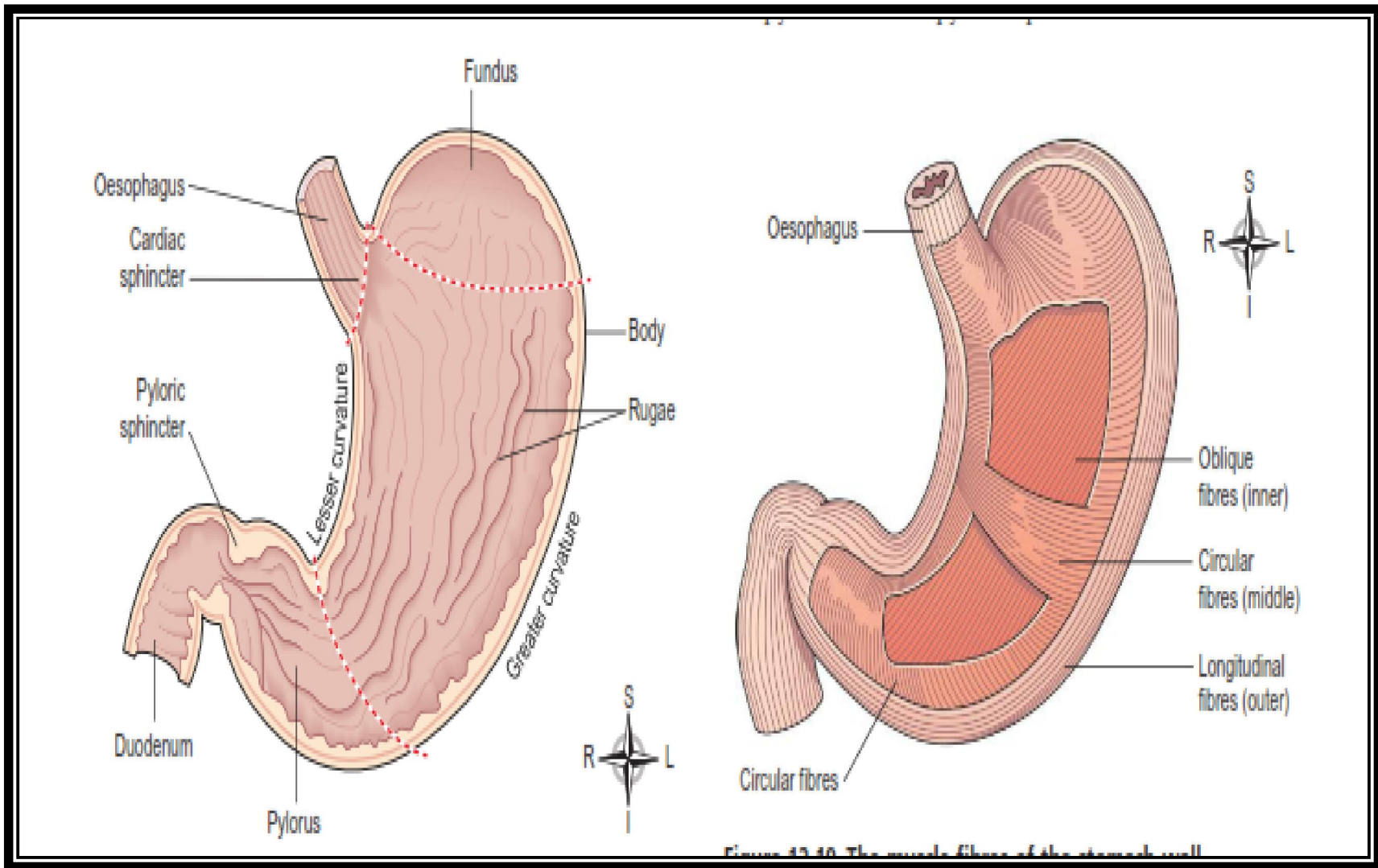


Fig: Longitudinal section of stomach

Fig: The muscle fibers of stomach wall

Walls of Stomach

The four layers of tissue that comprise the basic structure of the alimentary canal are found in the stomach but with some modifications.

Muscle layer: layers of smooth muscle fibres are:

- an outer layer of longitudinal fibres
- a middle layer of circular fibres
- an inner layer of oblique fibres.

Mucosa: When the stomach is empty the mucous membrane lining is thrown into longitudinal folds or rugae, and when full the rugae are 'ironed out' giving the surface a smooth, velvety appearance. Numerous gastric glands are situated below the surface in the mucous membrane and open on to it. They consist of specialised cells that secrete gastric juice into the stomach.

Secretion and control of Gastric Juice

About 2 litres of gastric juice are secreted daily by specialised secretory glands in the mucosa.

It consists of: water, mineral salts, mucus secreted by mucous neck cells in the glands and surface mucous cells on the stomach surface

hydrochloric acid

intrinsic factor

inactive enzyme precursors: pepsinogens secreted by *chief cells in the glands*.

A small quantity of gastric juice always present in the stomach, even when it contains no food.

This is known as fasting juice. Secretion reaches its maximum level about 1 hour after a meal then declines to the fasting level after about 4 hours.

Three phases of secretion of gastric juice are:

1. Cephalic phase. This flow of juice occurs before food reaches the stomach and is due to reflex stimulation of the vagus (parasympathetic) nerves initiated by the sight, smell or taste of food. When the vagus nerves have been cut (vagotomy), this phase of gastric secretion stops.

2. Gastric phase. When stimulated by the presence of food the enteroendocrine cells in the pylorus and duodenum secrete the hormone gastrin, which passes directly into the circulating blood. Gastrin, circulating in the blood which supplies the stomach, stimulates the gastric glands to produce more gastric juice. Gastrin secretion is suppressed when the pH in the pylorus falls to about 1.5.

3. Intestinal phase. When the partially digested contents of the stomach reach the small intestine, two hormones, secretin and cholecystokinin, are produced by endocrine cells in the intestinal mucosa. They slow down the secretion of gastric juice and reduce gastric motility.

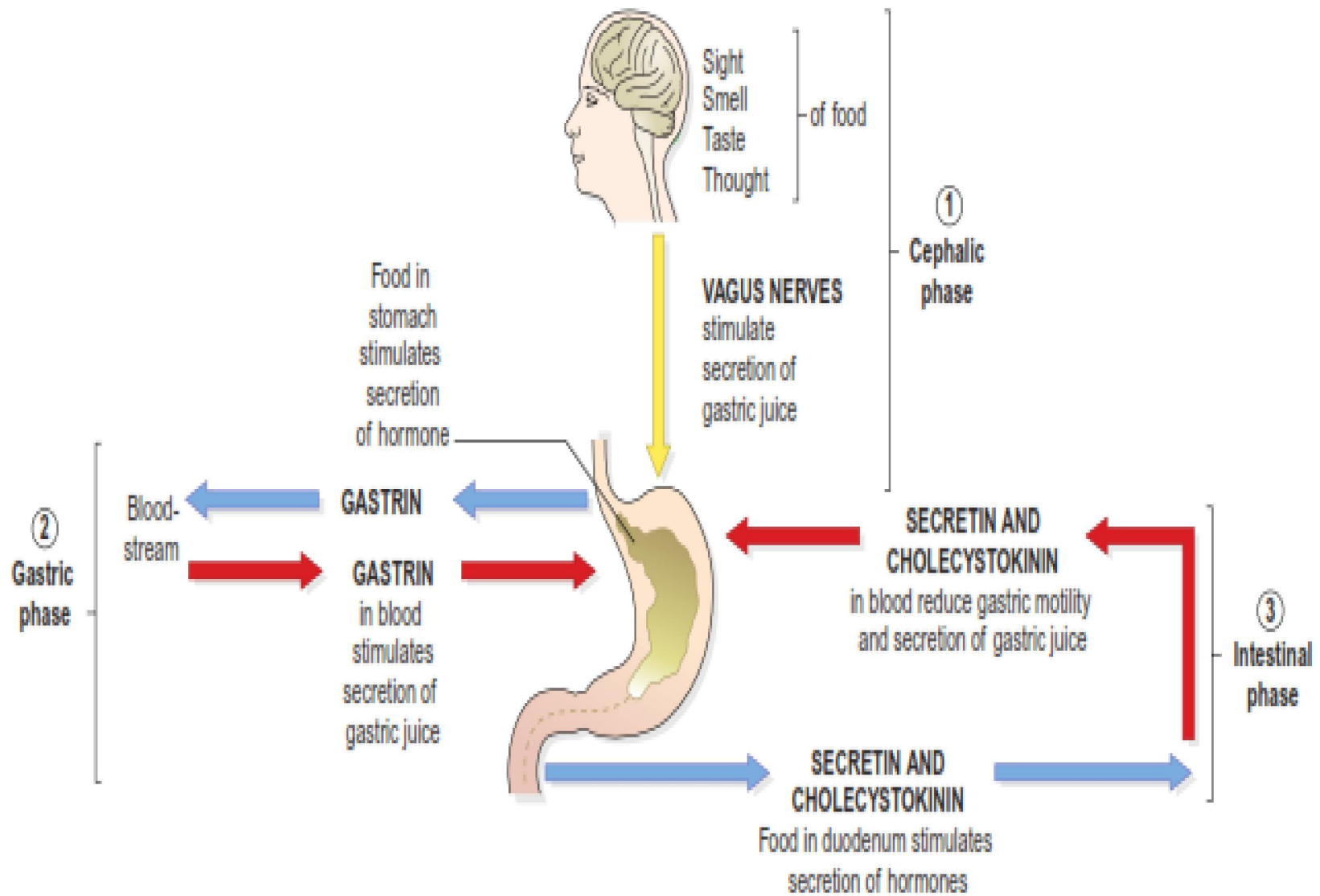


Fig: The three phases of secretion of gastric juice.



Small Intestine

- The small intestine is continuous with the stomach at the pyloric sphincter. The small intestine is about 2.5 cm in diameter, a little over 5 metres long and leads into the large intestine at the *ileocaecal valve*.
- *It lies in the abdominal cavity surrounded by the large intestine.*
- In the small intestine the chemical digestion of food is completed and absorption of most nutrients takes place.

The small intestine comprises three continuous parts....

- **Duodenum.** This is about 25 cm long and curves around the head of the pancreas. Secretions from the gall bladder and pancreas merge in a common structure – the *hepatopancreatic ampulla* – and enter the duodenum at the *duodenal papilla*.
- **Jejunum.** This is the middle section of the small intestine and is about 2 metres long.
- **Ileum.** This terminal section is about 3 metres long and ends at the *ileocaecal valve*, which controls the flow of material from the ileum to the *caecum*, the first part of the large intestine, and prevents backflow.

Structure of the small intestine

- The walls of the small intestine are composed of the four layers of tissue. Some modifications of the peritoneum and mucosa are described below.

Peritoneum

- The mesentery, a double layer of peritoneum, attaches the jejunum and ileum to the posterior abdominal wall. The large blood vessels and nerves lie on the posterior abdominal wall and the branches to the small intestine pass between the two layers of the mesentery.

Mucosa

- The surface area of the small intestine mucosa is increased by permanent circular folds, villi and microvilli.
- They promote mixing of chyme as it passes along.
- The villi are tiny finger-like projections of the mucosal layer into the intestinal lumen, about 0.5–1 mm long.
- Their covering consists of columnar epithelial cells with tiny microvilli (1 μm long).
- Goblet cells secrete mucus.
- These epithelial cells enclose a network of blood capillaries.

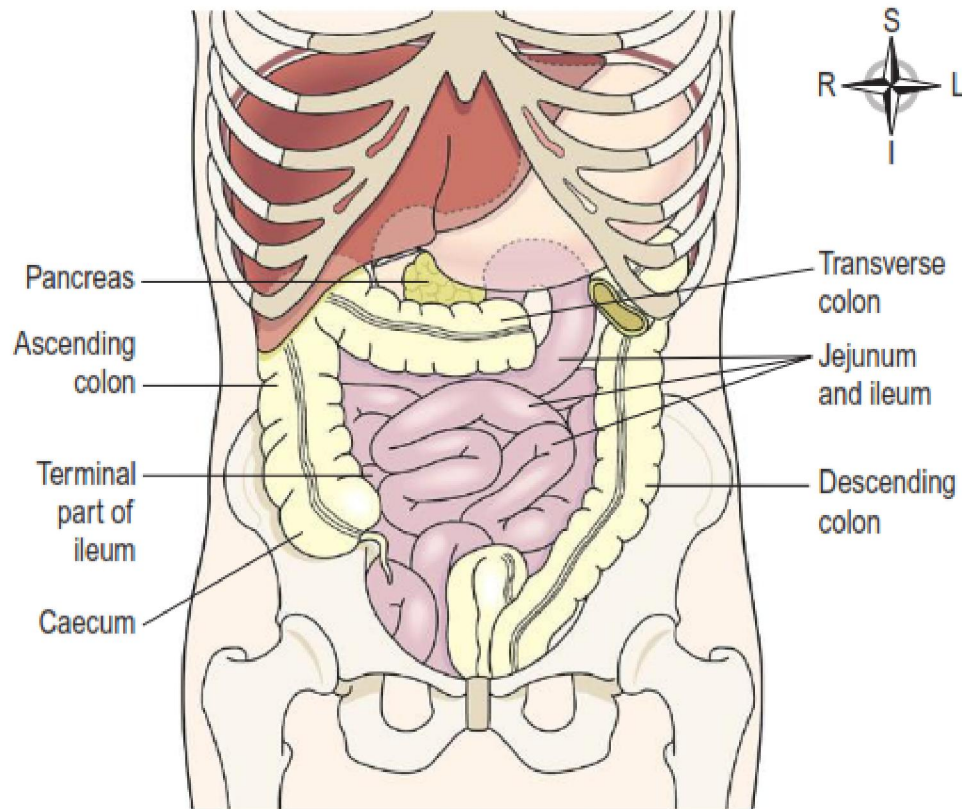


Fig: Small intestine and its parts.

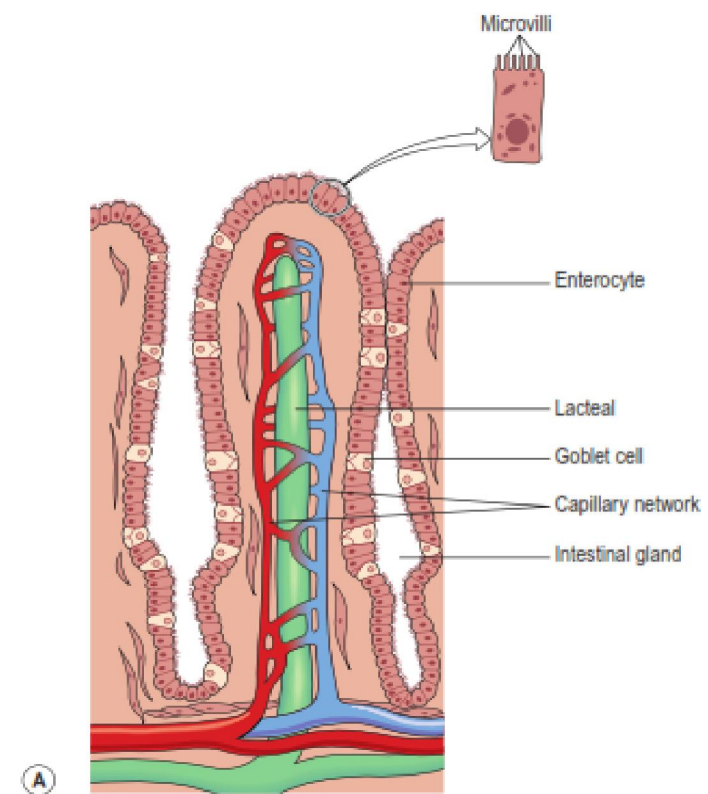


Fig: Villus of small intestine.

Blood supply

The superior mesenteric artery supplies the whole of the small intestine. Venous drainage is by the superior mesenteric vein that joins other veins to form the portal vein. The portal vein contains a high concentration of absorbed nutrients and this blood passes through the liver.

Functions of the small intestine

- Onward movement of its contents by peristalsis, which is increased by parasympathetic stimulation.
- Secretion of intestinal juice.
- Completion of chemical digestion of carbohydrates, protein and fats in the enterocytes of the villi.
- Protection against infection by microbes that have survived the antimicrobial action of the hydrochloric acid in the stomach.
- Secretion of the hormones cholecystokinin (CCK) and secretin.
- Absorption of nutrients.

Large Intestine

- The large intestine is about 1.5 metres long, beginning at the caecum in the right iliac fossa and terminating at the rectum and anal canal deep within the pelvis. Its lumen is about 6.5 cm in diameter, larger than that of the small intestine. It forms an arch round the coiled-up small intestine.

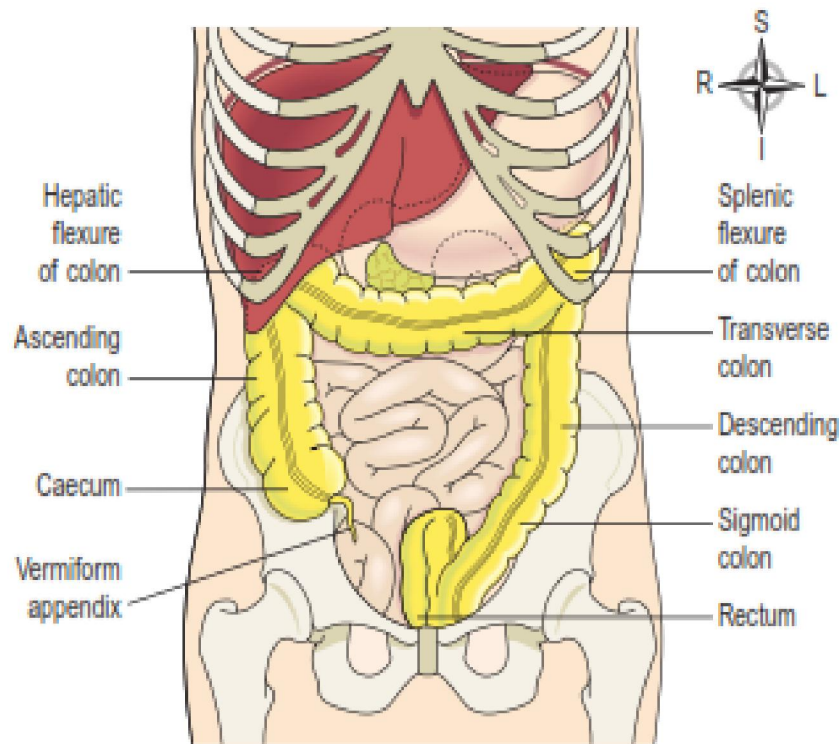


Fig: Large intestine and its parts.

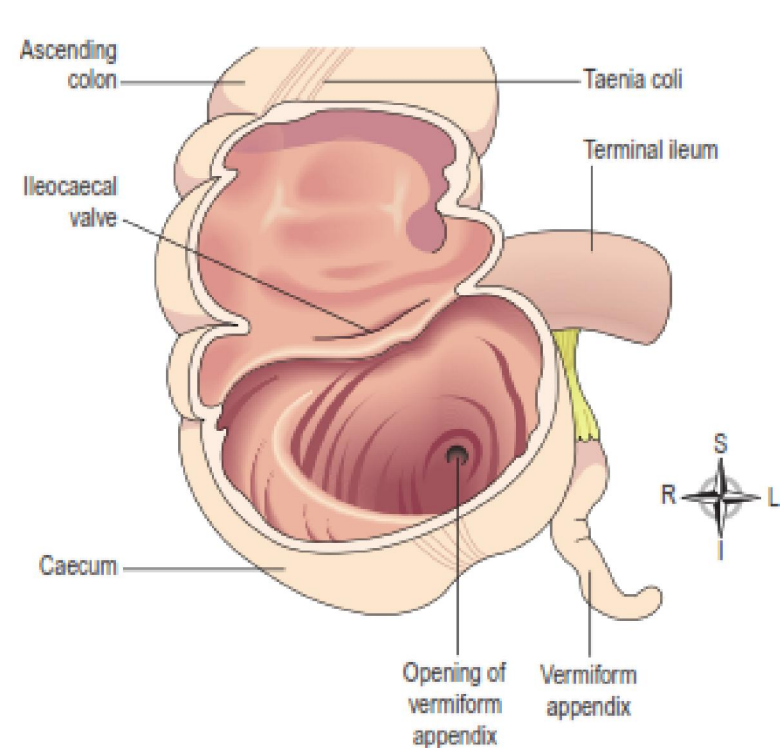


Fig: Interior of caecum.

The large intestine is divided into the

- I. Caecum
- II. Colon
- III. Sigmoid colon
- IV. Rectum
- V. Anal canal

The caecum

- First part of the large intestine, It is about 8-9 cm long.
- It is a dilated region which has a blind end inferiorly and is continuous with the ascending colon superiorly.
- Just below the junction of the two the ileocaecal valve opens from the ileum. The vermiform appendix is a fine tube, closed at one end, which leads from the caecum.

The colon

The colon has four parts which have the same structure and functions.

The ascending colon

Transverse colon

Descending colon

The sigmoid colon

The rectum

This is a slightly dilated section of the large intestine about 13 cm long. It leads from the sigmoid colon and terminates in the anal canal.

The anal canal

This is a short passage about 3.8 cm long in the adult and leads from the rectum to the exterior. Two sphincter muscles control the anus; the internal sphincter, consisting of smooth muscle, is under the control of the autonomic nervous system and the external sphincter, formed by skeletal muscle, is under voluntary control.

Structure

The four layers of tissue described in the basic structure of the gastrointestinal tract are present in the caecum, colon, the rectum and the anal canal. The arrangement of the longitudinal muscle fibres is modified in the caecum and colon. In the submucosal layer there is more lymphoid tissue than in any other part of the alimentary tract, providing non-specific defence against invasion by resident and other potentially harmful microbes.

In the mucosal lining of the colon and the upper region of the rectum are large numbers of mucus secreting goblet cells within simple tubular glands. They are not present beyond the junction between the rectum and the anal canal.

The lining membrane of the anal canal consists of stratified squamous epithelium continuous with the mucous membrane lining of the rectum above and which merges with the skin beyond the external anal sphincter. In the upper section of the anal canal the mucous membrane is arranged in 6-10 vertical folds, the anal columns. Each column contains a terminal branch of the superior rectal artery and vein.

Functions of the large intestine, rectum and anal canal

Absorption

The contents of the ileum which pass through the ileocaecal valve into the caecum are fluid, even though a large amount of water has been absorbed in the small intestine.

Microbial activity

The large intestine is heavily colonised by certain types of bacteria, which synthesise vitamin K and folic acid. They include *Escherichia coli*, *Enterobacter aerogenes*, *Streptococcus faecalis* and *Clostridium perfringens*. These microbes are commensals, i.e. normally harmless, in humans. However, they may become pathogenic if transferred to another part of the body,

Mass movement

The large intestine does not exhibit peristaltic movement. Only at fairly long intervals (about twice an hour) does a wave of strong peristalsis sweep along the transverse colon forcing its contents into the descending and sigmoid colons. This is known as *mass movement and it is often precipitated by* the entry of food into the stomach. This combination of stimulus and response is called the *gastrocolic reflex*.

Defaecation

Usually the rectum is empty, but when a mass movement forces the contents of the sigmoid colon into the rectum the nerve endings in its walls are stimulated by stretch. In infants, defaecation occurs by reflex (involuntary) action. However, during the second or third year of life children develop voluntary control of bowel function.

Salivary Glands

Salivary glands release their secretions into ducts that lead to the mouth. There are three main pairs: the parotid glands, the submandibular glands and the sublingual glands. There are also numerous smaller salivary glands scattered around the mouth.

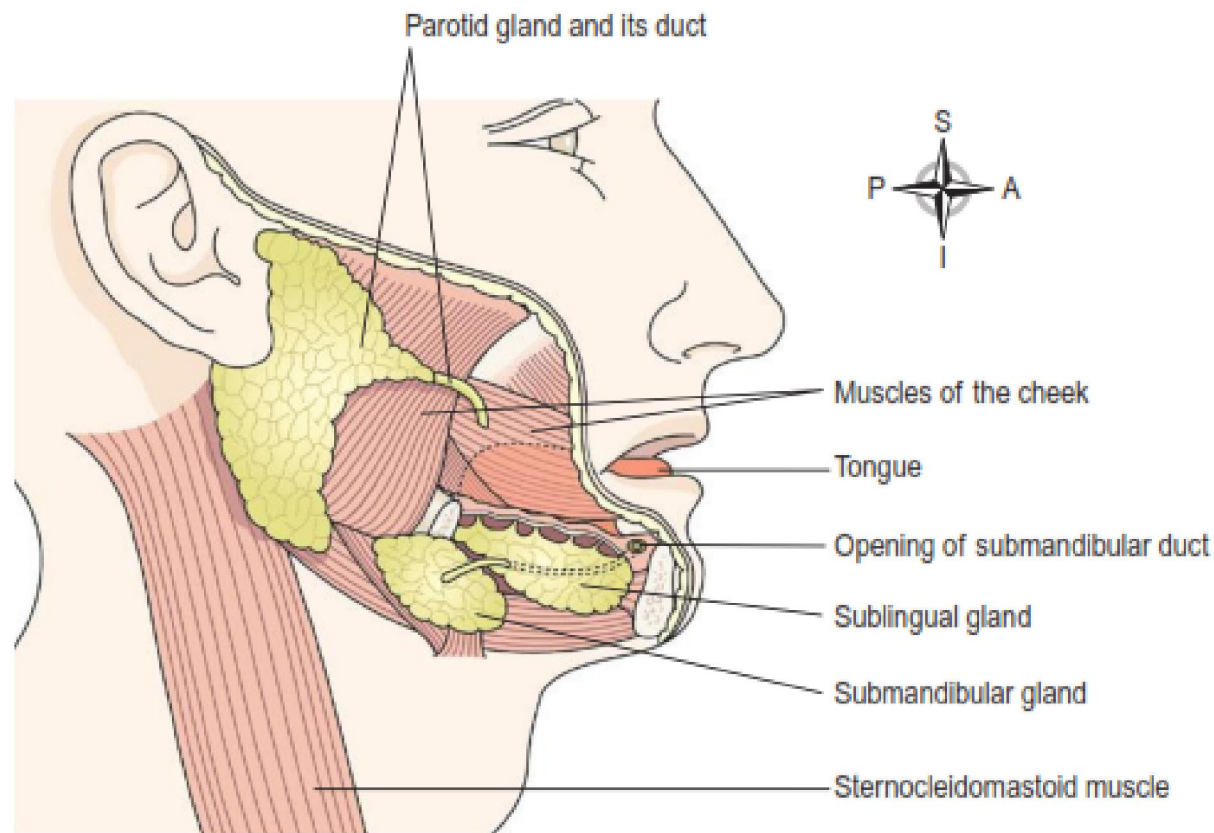


Fig: Salivary glands.

Parotid glands

These are situated one on each side of the face just below the external acoustic meatus. Each gland has a parotid duct opening into the mouth at the level of the second upper molar tooth.

Submandibular glands

These lie one on each side of the face under the angle of the jaw. The two submandibular ducts open on the floor of the mouth, one on each side of the frenulum of the tongue.

Sublingual glands

These glands lie under the mucous membrane of the floor of the mouth in front of the submandibular glands. They have numerous small ducts that open into the floor of the mouth.

Secretion of saliva

Secretion of saliva is controlled by the autonomic nervous system. Parasympathetic stimulation causes profuse secretion of watery saliva with a relatively low content of enzymes and other organic substances. Sympathetic stimulation results in secretion of small amounts of saliva rich in organic material, especially from the submandibular glands. Reflex secretion occurs when there is food in the mouth and the reflex can easily become *conditioned so that* the sight, smell and even the thought of food stimulates the flow of saliva.

Pancreas

The pancreas is a pale grey gland weighing about 60 grams. It is about 12-15 cm long and is situated in the epigastric and left hypochondriac regions of the abdominal cavity. It consists of a broad head, a body and a narrow tail. The head lies in the curve of the duodenum, the body behind the stomach and the tail lies in front of the left kidney and just reaches the spleen.

The pancreas is both an exocrine and endocrine gland.

The exocrine pancreas

This consists of a large number of lobules made up of small acini, the walls of which consist of secretory cells. Each lobule is drained by a tiny duct and these unite eventually to form the pancreatic duct, which extends along the whole length of the gland and opens into the duodenum. The function of the exocrine pancreas is to produce pancreatic juice containing enzymes, some in the form of inactive precursors, that digest carbohydrates, proteins and fats.

The endocrine pancreas

Distributed throughout the gland are groups of specialised cells called the pancreatic islets (of Langerhans). The islets have no ducts so the hormones diffuse directly into the blood. The endocrine pancreas secretes the hormones insulin and glucagon, which are principally concerned with control of blood glucose levels.

Liver

- The liver is the largest gland in the body, weighing between 1 and 2.3 kg. It is situated in the upper part of the abdominal cavity. Its upper and anterior surfaces are smooth and curved to fit the under surface of the diaphragm; its posterior surface is irregular in outline.
- The liver is enclosed in a thin inelastic capsule and incompletely covered by a layer of peritoneum. Folds of peritoneum form supporting ligaments that attach the liver to the inferior surface of the diaphragm.

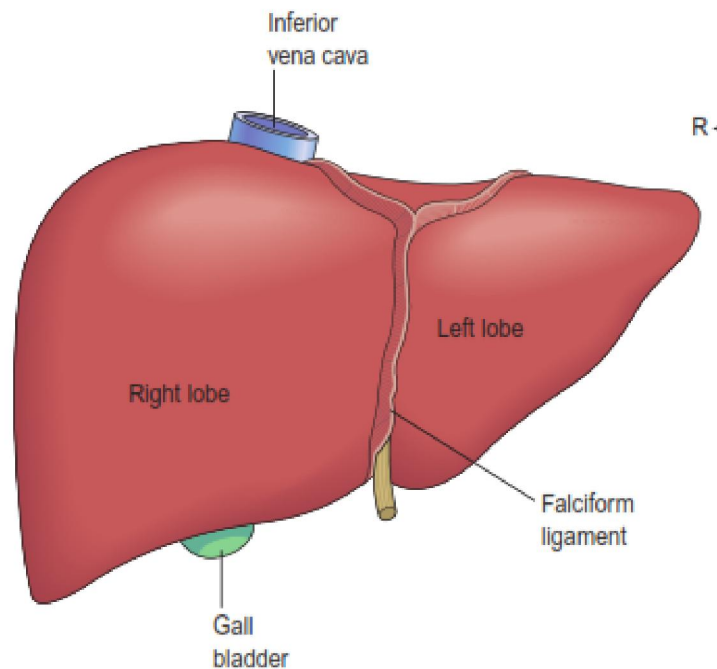


Fig: Anterior view of liver.

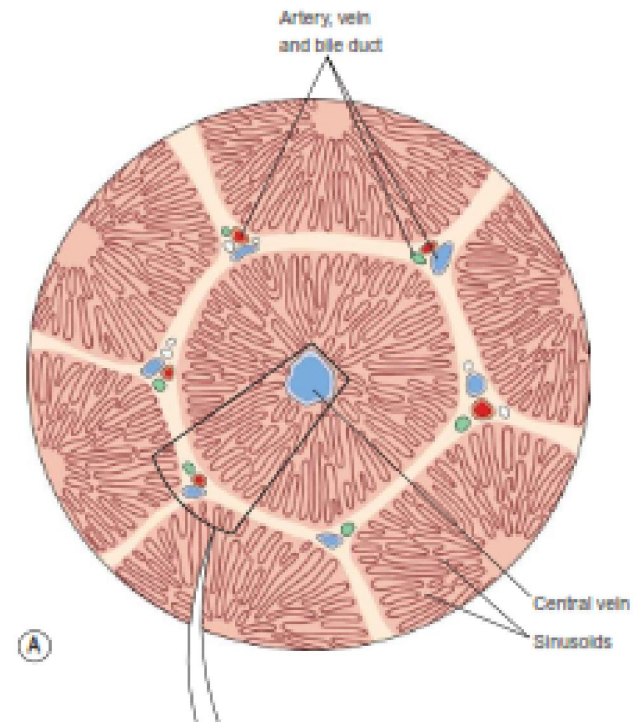


Fig: The liver lobules.

Structure of liver

The lobes of the liver are made up of tiny functional units, called lobules, which are just visible to the naked eye. Liver lobules are hexagonal in outline and are formed by cuboidal cells, the hepatocytes, arranged in pairs of columns radiating from a central vein. Between two pairs of columns of cells are sinusoids containing a mixture of blood from the tiny branches of the portal vein and hepatic artery. This arrangement allows the arterial blood and portal venous blood (with a high concentration of nutrients) to mix and come into close contact with the liver cells. Amongst the cells lining the sinusoids are hepatic macrophages (Kupffer cells) whose function is to ingest and destroy worn out blood cells and any foreign particles present in the blood flowing through the liver. Blood drains from the sinusoids into *central or centrilobular veins*. These then merge with veins from other lobules, forming larger veins, until eventually they become the hepatic veins, which leave the liver and empty into the inferior vena cava.

Thanks